

## Online Appendix 5 Indwelling pleural catheter (IPC) insertion technique

The following is a brief guide on the main points for indwelling pleural catheter (IPC) insertion. The operator should have adequate training including hands-on experience.

### Local anaesthesia

IPCs are often inserted using local anaesthetic without sedation, however sedation may be required for patient comfort in select cases.

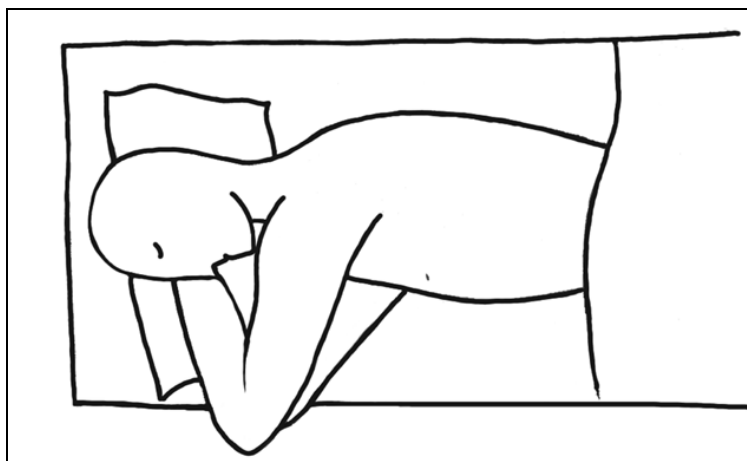
### Procedure for IPC insertion

The introducer needle is inserted in the pleural space at the pleural insertion site along the top of a rib, until pleural fluid is aspirated in a syringe attached to the introducer needle. The syringe is removed and a guidewire passed into the pleural space, through the introducer needle. The introducer needle is then removed, leaving the guidewire in place. A tear-away sheath dilator is inserted over the guidewire, and the guidewire and dilator removed, leaving the sheath in position. The fenestrated end of the IPC is then inserted through the sheath, into the pleural space, ensuring that all the fenestrations on the catheter tip lie within the pleural space. The sheath is then peeled away, leaving the catheter in position. The external end of the IPC is pulled gently through the skin exit site, ensuring that the catheter lies flat within the tunnel, avoiding kinks, and that the cuff lies within 1 cm from the skin exit site incision, within the subcutaneous tunnel, to facilitate eventual removal of the IPC.

The two incisions are closed with sutures – a closing suture applied to the pleural insertion site and a holding suture applied to the skin insertion site, although variation exists in suture techniques as not all operators leave a holding suture around the drain.<sup>1</sup> The IPC can then be connected to an underwater seal or an IPC drainage bottle, and in most centres, up to 1500 ml of pleural fluid is drained after IPC insertion. A chest x-ray can confirm correct IPC position and look for immediate complications (although pneumothorax may be indistinguishable from non-expandable lung). The patient is usually discharged home on the same day with an appropriate drainage plan.<sup>2</sup>

### Patient position

The patient is usually positioned in the lateral decubitus position (Figure 1), although IPC can be inserted in most positions that allow access to the pleural fluid. If a patient is unable to lie flat at 180 degrees, then elevation of the head of the bed or propping up with pillows may allow the patient to settle in a more comfortable position for the duration of the procedure.



**Figure 1:** Diagram of a patient in the right lateral decubitus position for a left sided IPC insertion. The arm ipsilateral to the IPC insertion side is elevated to widen the intercostal space, facilitating IPC insertion

Ultrasound in this position can confirm site, volume and loculation of the underlying pleural effusion. Ultrasound should also be used to mark the insertion points for the IPC (aiming for, or as close as possible to, the mid-axillary line for the pleural insertion site, and a second point about 7-10 cm along the same rib space anteriorly and inferiorly where the IPC will exit the skin). Anatomical variation, radiation burns, scars, and lung tethering,

as well as patient comfort, bra strap level, and ease of access may alter the chosen insertion sites. Ultrasound can also be used during the procedure allowing real-time guidance of instrumentation.

### Blunt dissection vs tunnelling

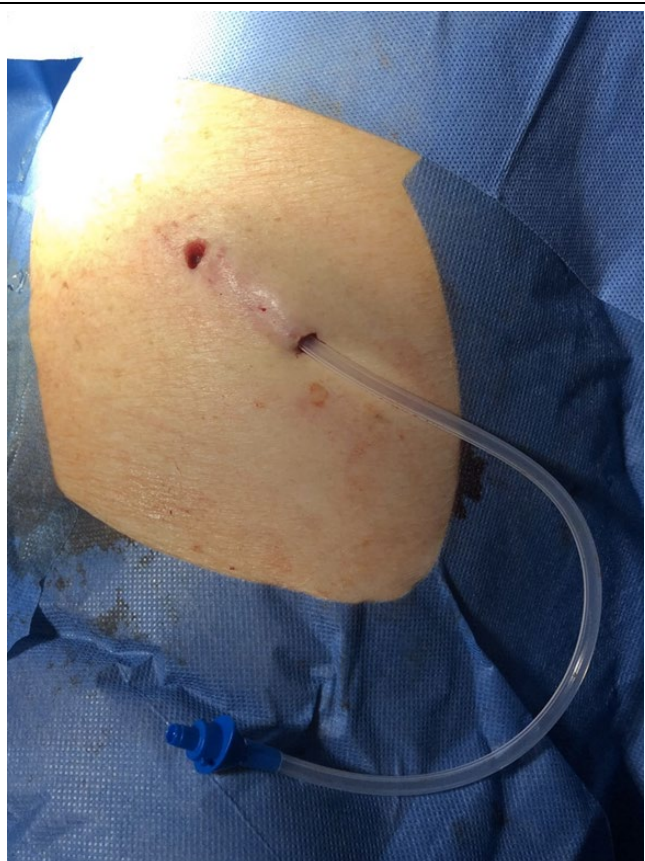After skin sterilisation and laying of sterile drapes, local anaesthetic is administered to the skin at the two chosen sites, the subcutaneous tissue along the tract between the sites, and to the pleura at the chosen pleural insertion site. Then, 1-2 cm incisions are made at the two chosen sites. A blunt tunnelling device or dissection with dissection forceps are used to create a tunnel through the subcutaneous tissues between the skin incisions, and the catheter passed through the tunnel from the skin exit site incision to the pleural insertion site incision, leaving the cuff sitting within the subcutaneous tunnel. The blunt tunnelling device is then removed from the proximal end of the catheter.

### Tunnel first or wire first

A modified Seldinger technique is then used to insert the IPC. Some operators will choose to insert the guidewire intrapleurally first, then create the subcutaneous tunnel second, and this is according to the instructions of IPC manufacturers (Rocket® and PleurX™). This gives reassurance that there is access to the pleural space prior to positioning the catheter within the subcutaneous tunnel. However, in practice, some operators prefer to tunnel the catheter subcutaneously prior to inserting the guidewire, with the advantage that the guidewire does not get in the way of the blunt dissection and tunnelling procedure. In addition, with standard practice now including ultrasound guidance for pleural procedures, including IPC insertion, it is easier to insert the IPC tip within the pleural space even after the subcutaneous tunnel has been created.

### Length of tract

Length of tract is usually recommended to be 5-10 cm (Figure 2).<sup>2,3</sup>



**Figure 2:** An IPC immediately after insertion, with a 5 cm subcutaneous tunnel, prior to sutures being applied

### Shorten catheter

The fenestrated end of the IPC may be cut shorter, depending on the patient's anatomy, to avoid discomfort from a long intrapleural catheter. However, adequate length of catheter should remain with multiple catheter fenestrations intrapleurally, to minimise chance of catheter blockage.

### Local anaesthetic plus adrenaline

Lignocaine 1% with or without adrenaline is generally recommended for chest drain insertion<sup>4</sup> and the British Thoracic Society 2010 guideline acknowledged that the combination is often used in some centres, although has not been studied in this setting.<sup>5</sup> The addition of adrenaline to lignocaine helps obtain haemostasis and allows larger doses of lidocaine to be infiltrated. It is commonly used for IPC insertion, including in trials<sup>6</sup>, although its use has not been studied in IPC insertion either.

### **Procedure for IPC removal**

IPC removal is usually carried out under local anaesthetic, dissecting around the cuff to free it of fibrous tissue that has anchored it in the subcutaneous tunnel, followed by manual retraction of the catheter.<sup>7</sup> The strongest point of adherence is usually towards the innermost part of the cuff.

### **References**

1. Bhatnagar R, Maskell NA. Indwelling pleural catheters. *Respiration*. 2014;88(1):74-85.
2. Welch HF, Bhatnagar R. Indwelling Pleural Catheters. In: Janes SM, ed. *Encyclopedia of Respiratory Medicine (Second Edition)*. Academic Press; 2022:607-620.
3. Rahman NM, Hunt I, Gleeson FV, Maskell N. *ABC of Pleural Diseases*. John Wiley & Sons Inc; 2018.
4. ACI Respiratory Network. Consensus Guideline - Pleural Drains in Adults. Available at: <[https://aci.health.nsw.gov.au/\\_data/assets/pdf\\_file/0018/201906/PleuralDrains\\_Guideline-021116.pdf](https://aci.health.nsw.gov.au/_data/assets/pdf_file/0018/201906/PleuralDrains_Guideline-021116.pdf)> [Accessed 22 May 2022].
5. Havelock T, Teoh R, Laws D, Gleeson F on behalf of the BTS Pleural Guideline Group. Pleural procedures and thoracic ultrasound: British Thoracic Society Pleural Disease Guideline 2010. *Thorax*. 2010;65 Suppl 2:ii61-76.
6. Martin GA, Tsim S, Kidd AC, et al. Pre-EDIT: protocol for a randomised feasibility trial of elastance-directed intrapleural catheter or talc pleurodesis (EDIT) in malignant pleural effusion. *BMJ Open Respir Res*. 2018;5(1):e000293.
7. Vali Y, Naaem M, Singh A, Rawson S, Reddy R. Incision-free removal of indwelling pleural catheters. *Thorax*. 2018;73(Suppl 4):A207–A208.